

[Orthopaedics]

Sportsmen's Groin—Diagnostic Approach and Treatment With the Minimal Repair Technique: A Single-Center Uncontrolled Clinical Review

Ulrike Muschaweck, MD, and Luise Masami Berger, MD*

Context: Sportsmen's groin, also called *sports hernia* and *Gilmore groin*, is one of the most frequent sports injuries in athletes and may place an athletic career at risk. It presents with acute or chronic groin pain exacerbated with physical activity. So far, there is little consensus regarding pathogenesis, diagnostic criteria, or treatment. There have been various attempts to explain the cause of the groin pain. The assumption is that a circumscribed weakness in the posterior wall of the inguinal canal, which leads to a localized bulge, induces a compression of the genital branch of the genitofemoral nerve, considered responsible for the symptoms.

Methods: The authors developed an innovative open suture repair—the Minimal Repair technique—to fit the needs of professional athletes. With this technique, the circumscribed weakness of the posterior wall of the inguinal canal is repaired by an elastic suture; the compression on the nerve is abolished, and the cause of the pain is removed. In contrast with that of common open suture repairs, the defect of the posterior wall is not enlarged, the suture is nearly tension free, and the patient can return to full training and athletic activity within a shorter time. The outcome of patients undergoing operations with the Minimal Repair technique was compared with that of commonly used surgical procedures.

Results: The following advantages of the Minimal Repair technique were found: no insertion of prosthetic mesh, no general anesthesia required, less traumatization, and lower risk of severe complications with equal or even faster convalescence. In 2009, a prospective cohort of 129 patients resumed training in 7 days and experienced complete pain relief in an average of 14 days. Professional athletes (67%) returned to full activity in 14 days (median).

Conclusion: The Minimal Repair technique is an effective and safe way to treat sportsmen's groin.

Keywords: sportsmen's groin; Minimal Repair technique; sports hernia; pubalgia; chronic groin pain; innovative surgery

Sportsmen's groin, also called *sports hernia* and *Gilmore groin*, is one of the most frequent sports injuries and represents a severe clinical problem, especially in athletes. Currently, there is little consensus regarding pathophysiology, diagnostic criteria, or treatment.

PATHOPHYSIOLOGY

There have been many attempts to explain the cause of groin pain, such as imbalance between the comparatively stronger hip adductor muscles and the comparatively weaker lower abdominal muscles.^{5,12} Weakness, poor endurance,

reduced extensibility, or poor coordination of the muscular synergists necessary for effective dynamic hip motion control may precipitate functional instability, overuse, and injury at comparatively weaker noncontractile structures.⁵

Among the existing theories, one suggests that the entrapment of the genital branch of the genitofemoral nerve or the ilioinguinal, lateral femoral cutaneous, and obturator nerves may be responsible for the pain.^{2,7,34} We principally agree with this assumption that the genital branch of the genitofemoral nerve is compressed by a localized bulge because of a circumscribed weakness in the posterior wall of the inguinal canal during the Valsalva maneuver (Figure 1).

From the Hernia Center Dr Muschaweck, Munich, Germany

*Address correspondence to Luise Masami Berger, MD, Hernienzentrum München, Arabellastr.5, München, Germany 81925 (e-mail: lui.berger@web.de).

No potential conflicts of interest declared.

DOI: 10.1177/1941738110367623

© 2010 The Author(s)

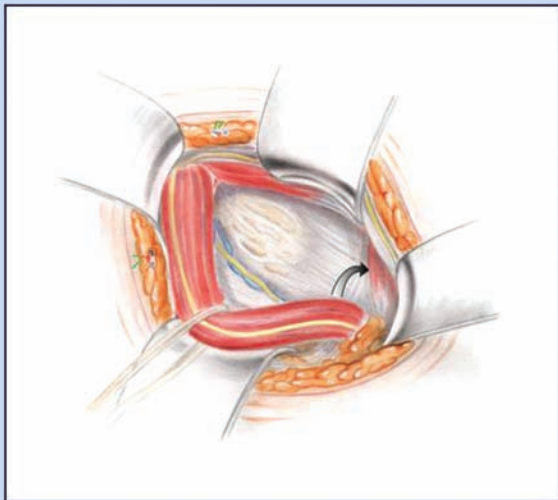


Figure 1. Cranial and medial displacement of the rectus abdominis muscle with increasing tension at the pubic bone.

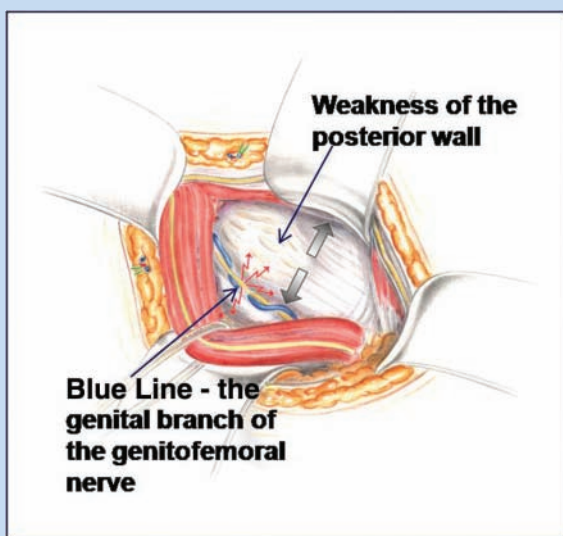


Figure 2. Sportsmen's groin, a localized bulge in the posterior inguinal wall with compression of the genital branch of the genitofemoral nerve.

As a consequence of the widened groin canal, the rectus muscle is retracted medially and cranially. This retraction causes an increased tension at the pubic bone. This pathomechanism is responsible for the pain at the symphysis pubis (Figure 1), also known as athletic pubalgia.

DIAGNOSIS

Diagnosis should be made by an experienced examiner because it may be difficult to distinguish the symptoms among different problems. Through a careful history, physical

examination, and dynamic ultrasonography, a correct diagnosis can be obtained.

Medical History

Sportsmen's groin presents with acute or chronic groin pain exacerbated with physical activity. The patient usually reports pain in the groin (dull, diffuse, sharp, and burning), often with radiation down the inner thigh, the scrotum, the testicle, and the pubic bone. In the early stages, the pain does not typically occur during competition but gives rise to aching afterward. Pain is aggravated by kicking, sudden changes in movement, coughing, and other Valsalva-type maneuvers.^{15,40} The pain can be so intense that athletes are impaired, severely constrained, or even completely disabled from training and practicing sport.

Physical Examination

The examination is carried out with the patient in upright position. When the inguinal canal is palpated, the patient usually confirms that the pain is getting worse. A sportsmen's groin is diagnosed when no inguinal hernia can be found but there is a localized bulge in the posterior wall of the inguinal canal during the Valsalva maneuver (Figure 2).

Dynamic Ultrasonography

Every patient should be explored with a dynamic ultrasound scan in supine position using a high-frequency transducer (5 MHz to 13 MHz). Care should be taken not to compress the inguinal canal with excessive transducer pressure. The motion of the inguinal canal and its walls is observed during the Valsalva maneuver, and the size of the defect can be measured (about 2 cm on average). Sportsmen's groin is diagnosed if a convex anterior bulge of the posterior inguinal wall is observed during stress. Magnetic resonance imaging (MRI) is reported to have good diagnostic potential,^{27,40} but the examination is done with the patient in the recumbent position. In our opinion, this explains the high rate of false-negative results with MRI and supports dynamic ultrasound scan as a diagnostically conclusive option, if it is done by an experienced examiner.

COMMON TREATMENT

The literature suggests that sportsmen's groin rarely improves without surgery.^{11,12,15,17,28,33} To avoid the development of chronic groin pain, surgical repair should be considered when conservative treatment over a period of 6 to 8 weeks has failed and when careful examination has excluded other potential pain sources.^{8,10,18,41} Both open and laparoscopic techniques produce excellent results, with most patients being able to return to their previous levels of activity.[†] So far, laparoscopic repair is believed to enable a faster recovery and return to unrestricted sports activities than that of open repair.^{8,16,24,37,40}

[†]References 1, 8, 25, 26, 33, 38-40, 42, 43.

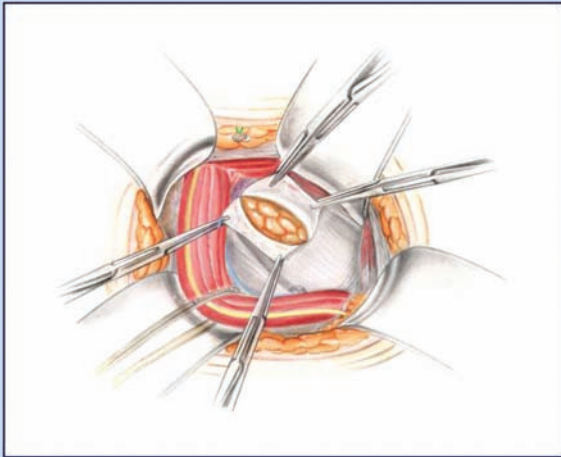


Figure 3. Only the defect is opened and, if necessary, resection of the genital branch of the genitofemoral nerve is performed.

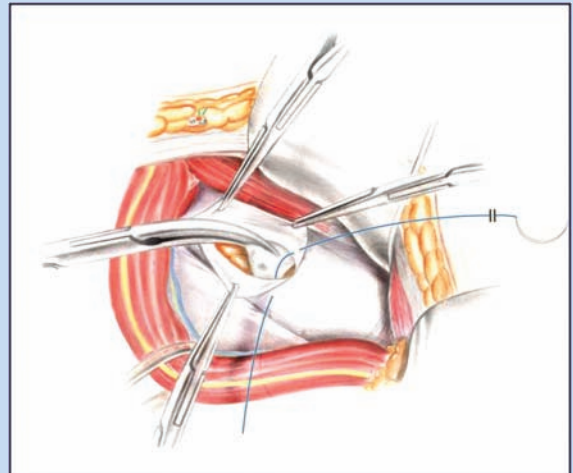


Figure 4. Suture 1: continuous suture (Prolene 2-0) from medial toward the deep inguinal ring, creating a free lip.

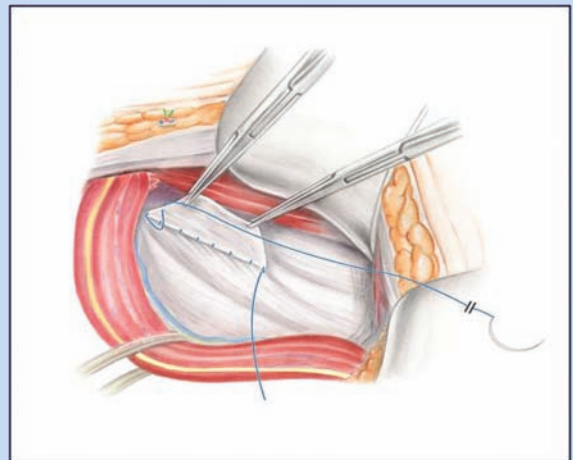


Figure 5. The suture now reverses its course toward the pubic bone, and the free border is included in the suture and brought to the inguinal ligament.

THE MINIMAL REPAIR TECHNIQUE

In 2003, we introduced an innovative open suture repair called the Minimal Repair technique.²⁹ We developed it to fit the needs of professional athletes. The aim of this surgical intervention is to eradicate groin pain by decompression of the genital branch of the genitofemoral nerve. The posterior wall is stabilized by a nearly tension-free suture without enlarging the defect of the posterior wall of the inguinal canal by the dissection. This allows the patient to return immediately to full activity without pain. As a general rule, we never use prosthetic mesh for athletes because they require, after surgery, the full elasticity and slide-bearing function of their abdominal muscles (ie, mobility of the 3 layers of the abdominal wall).

The Minimal Repair technique is performed under local anesthesia. The approach is carried out through a small inguinal incision, dissection of subcutaneous tissue, and splitting of the external oblique aponeurosis. The repair starts with testing the strength of the posterior inguinal wall by digital palpation. A circumscribed weakness is typically found in the posterior wall, with the surrounding tissue firm and intact. The fascia transversalis is split, beginning in the area of the defect toward the deep internal ring. The length of the incision encloses only the area of fascial weakness; the surrounding tissue is kept intact (Figure 3). The genital branch of the genitofemoral nerve should be assessed and, if necessary, partly removed (ie, because of nerve damage). Then a continuous suture is placed from medial toward the deep inguinal ring, creating a free fascia lip out of the iliopubic tract (suture 1; Figure 4). There, the suture reverses toward the pubic bone. The free lip is included in the suture and brought to the inguinal ligament (Figure 5). The rectus abdominis muscle is lateralized with suture to counteract the increased tension at the pubic bone caused by the retraction of the rectus

muscle in the superior and medial direction (suture 2; Figure 6). The pampiniform plexus is protected against mechanical irritation by creating a muscular collar at the deep ring with the lateral section of the internal oblique muscle (Figure 7). In contrast to the Shouldice repair, only the circumscribed weakness of the posterior wall is opened. Sound tissue next to the defect remains intact.

POSTOPERATIVE TREATMENT

Conventional nonsteroidal anti-inflammatory drugs are used for postoperative pain relief. All patients are discharged on the day of operation. Patients are allowed to lift up to 20 kg (44 lb) immediately after surgery, resume running or cycling

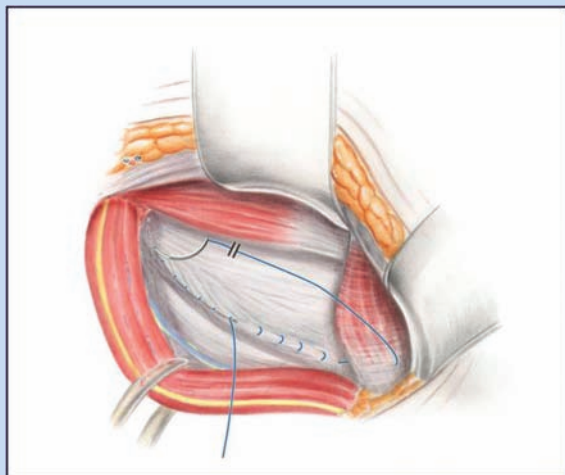


Figure 6. Suture 2: reducing the tension of the rectus abdominis muscle at the pubic bone.

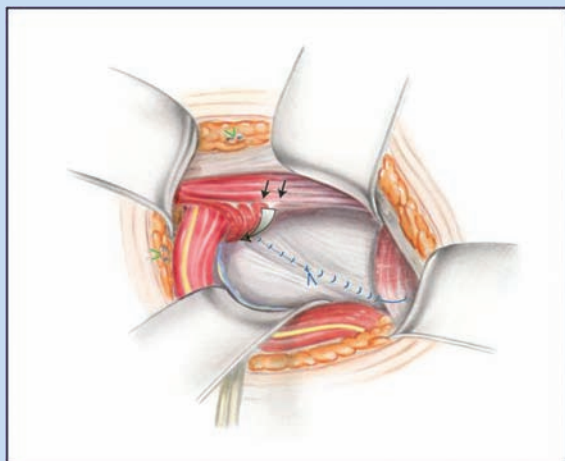


Figure 7. The lateral section of the internal oblique muscle creates a muscular collar to protect the pampiniform plexus and nerves from mechanical irritation.

on the second postoperative day, begin specific training on the third or fourth day, and fully train on the fifth. This is possible because the nearly tension-free suture does not cause pain.

RESULTS

Outcome at 4 Weeks

In 2009, a prospective cohort study was carried out to evaluate the clinical outcome of the Minimal Repair technique.²⁹ We report the results for the 4-week evaluation postoperatively. Further analysis will follow, given that the study is ongoing.

The primary endpoints were time to resume low-level training, full training and competing, and complete pain relief.

All but 5 patients (124 of 129; 96.1%) had resumed training (median, 7 days; interquartile range [IQR], 4 to 14). A full return to preinjury sports activity levels was reported by 75.8% (median, 18.5 days; IQR, 1.75 to 28.0), and 78.9% reported that they were completely free of pain (median, 14 days; IQR, 6 to 28 days). In professional athletes (67%), the time to return to preinjury sports activity was 14 days (IQR, 10 to 28).²⁹ Pain scores indicated a marked improvement in level of pain ($P < .0001$). The pain score decreased from 6 to 1 (IQRs, 3-7 and 0-2, respectively).²⁹ All patients thought that the operation had improved their symptoms considerably. Histologically, after nerve resection (genital branch of the genitofemoral nerve in 20%), a perineural fibrosis was shown in 100% of the patients.

Advantages of the Minimal Repair Technique

The Minimal Repair technique is a novel open repair technique where the preparation and doubling of the fascia transversalis encloses only the area of fascial weakness and does not affect surrounding sound tissue, as in standard suture repairs (eg, Shouldice repair).²⁹ Commonly used surgical procedures include open repairs (eg, Shouldice and Lichtenstein repairs) as well as laparoscopic repairs (eg, transabdominal preperitoneal procedure, total extraperitoneal procedure).

In comparison with the latter methods, the Minimal Repair technique has the following advantages: no insertion of prosthetic mesh, general anesthesia is not required, less traumatization, lower risk of severe complications, and equivalent or even faster convalescence.

Especially in athletes who require full elasticity and movement in their abdominal muscles, meshes should be avoided because, once inserted, they result in localized stiffening of the abdominal muscles and, therefore, restricted movement. Because Minimal Repair technique does not make use of meshes, patients are not prone to mesh-related complications, such as infections with chronic groin sepsis and fistula formation (which sometimes requires the removal of mesh³), mesh migration and penetration into the bladder or bowel,^{6,23} and foreign body reaction with decrease of arterial perfusion and testicular temperature³² with consecutive secondary azoospermia.³⁶ Of note, 35% of open procedures and 100% of laparoscopic procedures use mesh.⁸ Concerning the recurrence of pain so far, we have not had one case within our uncontrolled clinical review. In reviewing nearly 2000 minimal repairs in athletes since 2003, we have only 3 patients in which pain could not be permanently alleviated.

The laparoscopic approach always requires general anesthesia. This is not the case with open procedures, including the Minimal Repair technique; as such, patients are not exposed to the side effects of general anesthesia. Existing data from large consecutive patient series and randomized studies have shown local anesthesia to be advantageous.¹⁹

Open repairs were shown to be less traumatic than laparoscopic approaches.³⁵ Schwab et al determined the systemic inflammatory response after endoscopic versus Shouldice groin repair by monitoring cytokine activities (C-reactive protein, prostaglandin F_{1a}, neopterin, interleukin-6). The immune trauma was significantly higher in the group with laparoscopic hernia repair than in the group who received a Shouldice repair. Therefore, the repair of groin hernias using a laparoscopic technique should not be regarded as a minimally invasive procedure that is less traumatic than conventional approaches.³⁵ Because the Minimal Repair technique does not split the whole posterior inguinal wall, as in the case with a Shouldice repair, it can be considered less invasive with respect to tissue damage.

Severe visceral and vascular complications were more often reported with laparoscopic techniques⁴⁴ than with open repair techniques. A common problem after laparoscopic repair is postoperative urinary retention (22.2% after laparoscopic inguinal hernia procedures).²¹ The number of surgeons using laparoscopic procedures has increased in the past few years.^{13,17,20,30,39,42} With the Minimal Repair technique, neither minor nor major complications were observed during follow-up.

After laparoscopic repair, recovery generally took 6 to 8 weeks before full return to competition was permitted.^{1,8,15,22,42} The recovery times in other studies varied from 2 to 3 weeks,^{4,13} 4 weeks,³¹ 3 to 6 weeks,⁹ and up to 12 weeks.^{20,42} In a meta-analysis, Caudill et al found postsurgical recovery times (based on sports activity) of 17.7 weeks for patients who underwent open approaches and 6.1 weeks for laparoscopic repairs.⁸ Based on these data, the convalescence after operation under the Minimal Repair technique is faster than that after the customary procedures.

CONCLUSION

The Minimal Repair technique is an effective and safe way to treat sportsmen's groin.

REFERENCES

- Ahumada LA, Ashruf S, Espinosa-de-los-Monteros A, et al. Athletic pubalgia: definition and surgical treatment. *Ann Plast Surg.* 2005;55:393-396.
- Akita K, Niga S, Yamato Y, Muneta T, Sato T. Anatomic basis of chronic groin pain with special reference to sports hernia. *Surg Radiol Anat.* 1999;21:1-5.
- Avtan L, Avci C, Bulut T, Fourtanier G. Mesh infections after laparoscopic inguinal hernia repair. *Surg Laparosc Endosc.* 1997;7:192-195.
- Azurin DJ, Go LS, Schuricht A, McShane J, Bartolozzi A. Endoscopic preperitoneal herniorrhaphy in professional athletes with groin pain. *J Laparoendosc Adv Surg Tech A.* 1997;7:7-12.
- Biedert RM, Warnke K, Meyer S. Symphysis syndrome in athletes: surgical treatment for chronic lower abdominal, groin, and adductor pain in athletes. *Clin J Sport Med.* 2003;13:278-284.
- Bodenbach M, Bschiepfer T, Stoschek M, Beckert R, Sparwasser C. [Intravesical migration of a polypropylene mesh implant 3 years after laparoscopic transperitoneal hernioplasty]. *Urologe A.* 2002;41:366-368.
- Bradshaw C, McCrory P, Bell S, Bruckner P. Obturator nerve entrapment: a cause of groin pain in athletes. *Am J Sports Med.* 1997;25:402-408.
- Caudill P, Nyland J, Smith C, Yerasimides J, Lach J. Sports hernias: a systematic literature review. *Br J Sports Med.* 2008;42:954-964.
- Edelman DS, Selesnick H. "Sports" hernia: treatment with biologic mesh (Surgisis): a preliminary study. *Surg Endosc.* 2006;20:971-973.
- Ekberg O, Persson NH, Abrahamsson PA, Westlin NE, Lilja B. Longstanding groin pain in athletes: a multidisciplinary approach. *Sports Med.* 1988;6:56-61.
- Ekstrand J, Ringborg S. Surgery versus conservative treatment in soccer players with chronic groin pain: a prospective randomised study in soccer players. *European J Sports Traumatol Related Res.* 2001;23:141-145.
- Farber AJ, Wilckens JH. Sports hernia: diagnosis and therapeutic approach. *J Am Acad Orthop Surg.* 2007;15:507-514.
- Genitsaris M, Goulimaris I, Sikas N. Laparoscopic repair of groin pain in athletes. *Am J Sports Med.* 2004;32:1238-1242.
- Grant AM. Laparoscopic versus open groin hernia repair: meta-analysis of randomised trials based on individual patient data. *Hernia.* 2002;6:2-10.
- Hackney RG. The sports hernia: a cause of chronic groin pain. *Br J Sports Med.* 1993;27:58-62.
- Harmon KG. Evaluation of groin pain in athletes. *Curr Sports Med Rep.* 2007;6:354-361.
- Ingoldby CJ. Laparoscopic and conventional repair of groin disruption in sportsmen. *Br J Surg.* 1997;84:213-215.
- Joesting DR. Diagnosis and treatment of sportsman's hernia. *Curr Sports Med Rep.* 2002;1:121-124.
- Kehlet H, Aasvang E. Groin hernia repair: anesthesia. *World J Surg.* 2005;29:1058-1061.
- Kluin J, den Hoed PT, van Linschoten R, IJzerman JC, van Steensel CJ. Endoscopic evaluation and treatment of groin pain in the athlete. *Am J Sports Med.* 2004;32:944-949.
- Koch CA, Grinberg GG, Farley DR. Incidence and risk factors for urinary retention after endoscopic hernia repair. *Am J Surg.* 2006;191:381-385.
- Kumar A, Doran J, Batt ME, Nguyen-Van-Tam JS, Beckingham IJ. Results of inguinal canal repair in athletes with sports hernia. *J R Coll Surg Edinb.* 2002;47:561-565.
- Lange B, Langer C, Markus PM, Becker H. Mesh penetration of the sigmoid colon following a transabdominal preperitoneal hernia repair. *Surg Endosc.* 2003;17:157.
- Liem MS, van der Graaf Y, van Steensel CJ, et al. Comparison of conventional anterior surgery and laparoscopic surgery for inguinal-hernia repair. *N Engl J Med.* 1997;336:1541-1547.
- MacLeod DA, Gibbon WW. The sportsman's groin. *Br J Surg.* 1999;86:849-850.
- Malycha P, Lovell G. Inguinal surgery in athletes with chronic groin pain: the "sportsman's" hernia. *Aust N Z J Surg.* 1992;62:123-125.
- Meyers WC, McKechnie A, Philippon MJ, Horner MA, Zoga AC, Devon ON. Experience with "sports hernia" spanning two decades. *Ann Surg.* 2008;248:656-665.
- Moeller JL. Sportsman's hernia. *Curr Sports Med Rep.* 2007;6:111-114.
- Muschaweck U, Berger L. Minimal repair technique of sportsmen's groin: an innovative open-suture repair to treat chronic inguinal pain. *Hernia.* In press.
- Paajanen H, Heikkinen J, Hermunen H, Airo I. Successful treatment of osteitis pubis by using totally extraperitoneal endoscopic technique. *Int J Sports Med.* 2005;26:303-306.
- Paajanen H, Syvahuoko I, Airo I. Totally extraperitoneal endoscopic (TEP) treatment of sportsman's hernia. *Surg Laparosc Endosc Percutan Tech.* 2004;14:215-218.
- Peiper C, Junge K, Klinge U, Strehlau E, Ottinger A, Schumpelick V. Is there a risk of infertility after inguinal mesh repair? Experimental studies in the pig and the rabbit. *Hernia.* 2006;10:7-12.
- Polglase AL, Frydman GM, Farmer KC. Inguinal surgery for debilitating chronic groin pain in athletes. *Med J Aust.* 1991;155:674-677.
- Rab M, Elmer J, Dellon AL. Anatomic variability of the ilioinguinal and genitofemoral nerve: implications for the treatment of groin pain. *Plast Reconstr Surg.* 2001;108:1618-1623.
- Schwab R, Eissele S, Bruckner UB, Gebhard F, Becker HP. Systemic inflammatory response after endoscopic (TEP) vs Shouldice groin hernia repair. *Hernia.* 2004;8:226-232.
- Shin D, Lipshultz LI, Goldstein M, et al. Herniorrhaphy with polypropylene mesh causing inguinal vasal obstruction: a preventable cause of obstructive azoospermia. *Ann Surg.* 2005;241:553-558.
- Srinivasan A, Schuricht A. Long-term follow-up of laparoscopic preperitoneal hernia repair in professional athletes. *J Laparoendosc Adv Surg Tech A.* 2002;12:101-106.
- Steele P, Annear P, Grove JR. Surgery for posterior inguinal wall deficiency in athletes. *J Sci Med Sport.* 2004;7:415-421.

39. Susmallian S, Ezri T, Elis M, Warters R, Charuzi I, Muggia-Sullam M. Laparoscopic repair of "sportsman's hernia" in soccer players as treatment of chronic inguinal pain. *Med Sci Monit.* 2004;10:52-54.
40. Swan KG Jr, Wolcott M. The athletic hernia: a systematic review. *Clin Orthop Relat Res.* 2007;455:78-87.
41. Van Der Donckt K, Steenbrugge F, Van Den Abbeele K, Verdonk R, Verhelst M. Bassini's hernial repair and adductor longus tenotomy in the treatment of chronic groin pain in athletes. *Acta Orthop Belg.* 2003;69:35-41.
42. van Veen RN, de Baat P, Heijboer MP, et al. Successful endoscopic treatment of chronic groin pain in athletes. *Surg Endosc.* 2007;21:189-193.
43. Ziprin P, Prabhudesai SG, Abrahams S, Chadwick SJ. Transabdominal preperitoneal laparoscopic approach for the treatment of sportsman's hernia. *J Laparoendosc Adv Surg Tech A.* 2008;18:669-672.

For reprints and permissions queries, please visit SAGE's Web site at <http://www.sagepub.com/journalsPermissions.nav>.