

19 outbreak. *Dermatol Ther* 2020; <https://doi.org/10.1111/dth.13680>.

Funding sources: none.

Conflicts of interest: Dr. Lima serves on the speakers' bureau for Abbvie. Mary Cueva has no relevant conflicts of interest. Dr. Alora has been an investigator for Abbvie, Janssen, Celgene, Eli Lilly, Pfizer, Inc., Novartis.

Prevalence of mucocutaneous manifestations in 666 patients with COVID-19 in a field hospital in Spain: oral and palmoplantar findings

DOI: 10.1111/bjd.19564

DEAR EDITOR, Coronavirus disease 2019 (COVID-19) has been associated with several cutaneous manifestations.^{1–3} A temporary field hospital was implemented during the pandemic peak in Madrid, Spain, to attend patients with COVID-19 who had mild-to-moderate pneumonia. A team of dermatologists working as medical volunteers performed a cross-sectional study between 10 and 25 April 2020 to evaluate cutaneous findings of such patients.

A total of 666 patients with COVID-19 fulfilled the inclusion criteria: either positive real-time reverse-transcription polymerase chain reaction (RT-PCR) testing for SARS-CoV-2, or bilateral pneumonia. Mean age was 55.7 years; with a slight female predominance (58%). Notably, 47.1% were from Latin America.

Overall, 304 (45.7%) of our patients presented with one or more mucocutaneous manifestations. Oral cavity findings were seen in 78 cases (25.7%), including transient lingual papillitis (11.5%), glossitis with lateral indentations (6.6%) (Figure 1a), aphthous stomatitis (6.9%), glossitis with patchy depapillation (3.9%) (Figure 1b) and mucositis (3.9%). Burning sensation was reported in 5.3% of patients, and taste disturbances (dysgeusia) were commonly associated.

Palmoplantar involvement was observed in 121 patients (39.8%) and included diffuse desquamation in 77 (25.3%), often favouring the weight-bearing areas, and reddish-to-brown acral macules on palms and soles in 46 (15.1%) (Figure 1c, d). Mild pruritus was occasionally reported. Fungal cultures of plantar desquamation performed in nine patients ruled out superficial mycoses. Histological study from the acral macules was performed in four patients, showing a mild-to-moderate lymphocytic infiltrate surrounding the blood vessels and eccrine sweat glands. Seven per cent of the patients reported burning sensation (erythrodysesthesia) at the beginning of the disease.

Urticaria (6.9%), rash (2.9%) and vesicular eruptions (1.6%) were observed in a minority of patients. While urticaria and rash were observed at any stage of the COVID-19

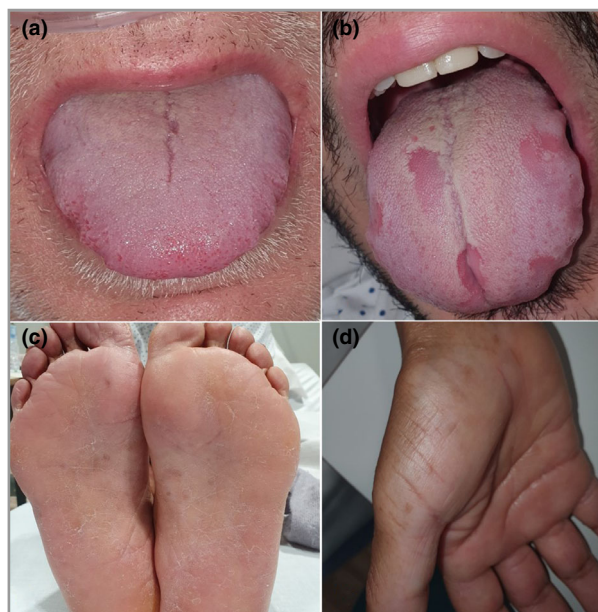

Figure 1 Upper panel shows COVID-19 oral mucosa findings. (a) Glossitis with lateral indentations and anterior transient lingual papillitis due to swelling of the tongue and friction with the teeth. (b) Glossitis with patchy depapillation. Lower panel shows palmoplantar findings in patients with COVID-19. (c) Reddish-to-brown acral macules with a slight desquamation on the feet of a patient. Pathology excluded racial pigmentation, showing mild-to-moderate lymphocytic infiltrate surrounding the blood vessels and eccrine sweat glands. (d) Acral macules on the palm of a patient with COVID-19 with the same histopathology.

infection, vesicular eruptions typically appeared within the first few days of symptoms. Both urticaria and vesicular eruptions appeared in younger patients than did the other mucocutaneous manifestations, with statistical significance ($P = 0.024$).

Prior studies^{2,3} have found a significantly lower prevalence of COVID-19-associated dermatoses (20% and 7.8%, respectively). The higher prevalence in our study may be due to additional findings not previously described. Although the oral cavity is frequently involved in viral infections, glossitis or papillitis have not been described in patients with COVID-19.⁴ However, these differences could also be due to the conditions during hospitalization including ventilation masks, for example. We hypothesize that the contagion risk while examining the oral cavity might have precluded a thorough physical examination in these patients.

Palmoplantar involvement was also a frequent finding. Some patients recalled a burning sensation and redness or swelling of the hands or feet shortly after COVID-19 symptoms began. Erythrodysesthesia is a common complaint secondary to cancer chemotherapy that is thought to be related to direct drug toxicity and inflammation of the eccrine glands.⁵ Interestingly, several outbreaks of poxvirus-related erythromelalgia have been reported in China. The first outbreak occurred in Wuhan in 1987, and all patients had

respiratory symptoms as well as redness and swelling of the hands and feet.⁶ Also, burning sensation has been described in chilblain-like lesions¹ and there is one self-reported case of a physician with COVID-19 complaining of a 'pins and needles' sensation in palms and soles with subsequent appearance of acral macules.



Diffuse asymptomatic palmoplantar desquamation was another common but previously unreported finding. Although it could be related to other common conditions such as tinea pedis, patients denied its prior existence and fungal infection was excluded in nine of 121 patients.




Skin rashes were relatively uncommon, being observed in 11.6% of our patients. Although a variety of rashes have been previously reported¹ both in children and adults,^{7,8} the exact prevalence, time of onset and age specificity remains unknown. Interestingly, pseudo-chilblains have been commonly observed in children¹ (some of them with negative RT-PCR or serological tests) but were absent in our 666 patients, supporting the age-specificity trend.

Our study has several limitations. Firstly, we only included patients with mild-to-moderate COVID-19 pneumonia and cannot provide data on skin disease in asymptomatic patients or with more severe forms of COVID-19. Secondly, all patients were adults, and the prevalence of mucocutaneous findings may be different in children. Thirdly, as our work was performed in a 2-week period, we may have missed earlier or late cutaneous manifestations of COVID-19.

In summary, almost half of patients with mild-to-moderate COVID-19 admitted in a field-hospital during a 2-week period showed mucocutaneous findings. The oral cavity was frequently involved and deserves specific examination under appropriate circumstances to avoid contagion risk. Redness and swelling of the hands and feet, fine palmoplantar desquamation and reddish-to-brown macules can help us to diagnose COVID-19 infection and should be routinely checked.

Acknowledgments: We would like to thank Dr Angela Hernandez-Martín for her valuable comments during the preparation of this paper.

A. Nuno-Gonzalez ^{1,2} P. Martín-Carrillo,^{3,4}
K. Magaletsky,^{1,2} M.D. Martín Ríos,⁵ C. Herranz Mañas,¹
J. Artigas Almazan,¹ G. García Casasola ^{6,7} E. Pérez Castro,⁴

A. Gallego Arenas,⁸ A. Mayor Ibarguren,^{1,2}
M. Feito Rodríguez ^{1,2} B. Lozano Masdemont ⁹
M. Beato,¹⁰ E. Ruiz Bravo,¹⁰ P. Oliver,¹¹ M.D. Montero Vega¹²
and P. Herranz Pinto ^{1,2}

Departments of ¹Dermatology, ¹⁰Pathology, ¹¹Laboratory Medicine and ¹²Microbiology, Hospital Universitario La Paz, Madrid, Spain; ²Facultad de Medicina, Universidad Autónoma de Madrid, Madrid, Spain; ³SERMAS, Madrid, Spain; ⁴Centro de Salud de Colmenarejo, Madrid, Spain; ⁵Department of Preventive Medicine, Hospital Universitario Fundación Jiménez Díaz, Madrid, Spain; ⁶Department of Internal Medicine, Hospital Universitario Infanta Sofía, Madrid, Spain; ⁷Facultad de Medicina, Universidad Complutense de Madrid, Madrid, Spain; ⁸Centro de Salud Presentación Sabio, Móstoles, Madrid, Spain; and ⁹Department of Dermatology, Hospital Universitario Móstoles, Madrid, Spain

Email: dra.almudenanunogonzalez@gmail.com

References

- Galván Casas C, Català A, Carretero Hernández G et al. Classification of the cutaneous manifestations of COVID-19: a rapid prospective nationwide consensus study in Spain with 375 cases. *Br J Dermatol* 2020; **183**:71–7.
- Recalcati S. Cutaneous manifestations in COVID-19: a first perspective. *J Eur Acad Dermatol Venereol* 2020; **34**:e212–13.
- De Giorgi V, Recalcati S, Jia Z et al. Cutaneous manifestations related to coronavirus disease 2019 (COVID-19): a prospective study from China and Italy. *J Am Acad Dermatol* 2020; **83**:674–5.
- Jimenez-Cauhe J, Ortega-Quijano D, de Perosanz-Lobo D et al. Enanthem in patients with COVID-19 and skin rash. *JAMA Dermatol* 2020; <https://doi.org/10.1001/jamadermatol.2020.2550>.
- Hueso L, Sanmartín O, Nagore E et al. [Chemotherapy-induced acral erythema: a clinical and histopathologic study of 44 cases]. *Actas Dermosifiliogr* 2008; **99**:281–90 (in Spanish).
- Mendez-Rios JD, Martens CA, Bruno DP et al. Genome sequence of erythromelalgia-related poxvirus identifies it as an ectromelia virus strain. *PLoS One* 2012; **7**:e34604.
- Marzano AV, Genovese G, Fabbrocini G et al. Varicella-like exanthem as a specific COVID-19-associated skin manifestation: multicenter case series of 22 patients. *J Am Acad Dermatol* 2020; **83**:280–5.
- van Damme C, Berlingin E, Saussez S, Accaputo O. Acute urticaria with pyrexia as the first manifestations of a COVID-19 infection. *J Eur Acad Dermatol Venereol* 2020; **34**:e300–1.

Funding sources: none.

Conflicts of interest: The authors declare they have no conflicts of interest.